


What's **Next** in Laser and OCT?

Swept-source OCT and
Non-damaging Laser Treatment



Sponsored by

REVIEW
of Ophthalmology

Supported by

 **TOPCON**
CONNECTING VISIONS

What's Next in Laser and OCT?

Swept-source OCT and Non-damaging Laser Treatment

Topcon Corporation is known for many innovative products, and is celebrating its 80th anniversary this year. Noteworthy of the company's products is its first lensmeter (the Lensmeter I), which it introduced in 1947, as well as the first Simultaneous Stereo Retinal Camera, the TRC. Also of significance is the fact that Topcon was the first company to commercially introduce spectral-domain optical coherence tomography to the market in 2007 and continues to advance that product line.

In light of this considerable achievement, it is only fitting to highlight the company's two latest product advancements in laser treatment and swept-source OCT: Deep Range Imaging (DRI) OCT-1 Atlantis, and the PASCAL Photocoagulator with Endpoint Management. Three well-known ophthalmologists, Robert N. Weinreb, MD, Richard Spaide, MD, and Pravin Dugel, MD, recently spoke about these new technologies, sharing both their knowledge and experience, which has been conveniently summarized for you in the following pages.

Imaging the Depths of the Eye

The latest in imaging technology enables practitioners to see more ocular structures and in greater detail, opening the door to better management and treatment of various conditions.

Richard F. Spaide, MD

The most common optical coherence tomography imaging used today is spectral-domain OCT. Prior to the advent of SD-OCT, time-domain OCT ruled the day. The resolution of TD instruments can be good, particularly for stationary subjects, but one important limitation was its slow scan speed. SD-OCT is capable of operating nearly 100 times faster than TD-OCT and consequently, it was possible to build instruments that had high scan densities with greatly decreased time needed for the scan.

More recently, a new type of OCT methodology has been

commercially introduced with Topcon's Deep Range Imaging (DRI) OCT-1 Atlantis. This OCT instrument uses swept-source technology to overcome some of the more important weaknesses of SD-OCT. TD-OCT was capable of visualizing the vitreous and retina to some extent, and with each iteration of OCT technology, the depth of visualization has increased. It is now possible for us to look at the vitreous, optic nerve, sclera and choroid all in one scan. Let's take a look at how OCTs work to get a better appreciation of all that they offer.

OCT FUNCTIONALITY

SD-OCT was the latest and greatest a few years ago, and still is a good technology, but it is not without its limitations. The instrument produces a wide band of wavelengths, and the light penetrates the inside of the eye, reflecting off various structures such as the different

retinal layers. When it comes back, it joins with another set of light rays that has gone through a reference arm, which has a fixed length. When the two combine together in an interferometer, it creates an interference fringe, which has a set of frequencies that varies with the depth of the reflectors inside the eye. So we can get a reflection with a certain strength and frequency back from the eye. In other words, the reflection is depth-encoded by frequency. We can then decode that frequency with a Fourier transform and get the location of the reflecting structure. If we change the position of the reflector to be a bit deeper in the eye, the interference fringe would have a higher frequency.

The retina has many reflections from many structures, and many different frequencies are all mixed together, which is where the power of the Fourier transform comes into play. This

transform decodes the combined reflectance signal into a wave form that contains structural reflectance in depth; that's the A-scan. When we put a lot of A-scans together, we get a B-scan. A B-scan is a cross-sectional view of the retina.

The key to SD-OCT hinges on the fact that the greater the mismatch or depth inside the eye, the higher the frequency of the interference fringes.

This leads to the weakness of SD-OCT because the detection method used in SD-OCT is less sensitive at higher frequencies. That produces a roll-off of sensitivity of the detector versus depth in the eye. Simply stated, the deeper you are inside the eye, the less sensitive the OCT detection system is to the ensuing reflection and, consequently, the lower the signal-to-noise ratio of that portion of the image.

Ordinarily, with SD-OCT, we have an area with high sensitivity that is usually placed in the vitreous above the retinal surface. That's because the vitreous, which is ordinarily a clear structure, is hard to see, so we put our high sensitivity in the area where we're not going to get a very strong signal. We can push that sensitivity curve deeper into the eye, giving us the highest sensitivity near the sclera and choroid. We call this method **enhanced depth imaging OCT, or EDI**. In this case, the sensitivity curve is placed at the inner sclera, so the vitreous, which ordinarily is dark, looks even darker because there's not much signal originating from there, and the OCT sensitivity is now low in that location.

Spectral Domain OCT vs. Swept Source OCT

	Spectral Domain (3D OCT-2000)	Swept-source OCT (DRI OCT-1)
Light source	spectral domain	swept source
Wavelength	840 nm	1,050 nm
Scan speed	25,000 A-scans/sec	100,000 A-scans/sec
B-scan acquisition time (resolution: line 1,024)	approx. 0.04 sec	approx. 0.01 sec
3D scan acquisition time (resolution: 3D 512 x 128)	approx. 2.6 sec	approx. 0.65 sec
Maximum overlapping scan count (resolution: line 1,024, 3D 512 x 64)	max. 50 line (3D n/a)	max. 96 line (3D max. 4)

The inner retinal layers can be somewhat darker for the same reason. The bottom line is, with SD-OCT, you can get high sensitivity and good image quality either at the top of the image or the bottom, but not both at the same time.

Swept-source OCT works on a different principle. A tunable laser scans through a range of individual wavelengths sequentially, building up the interferogram in a very rapid sort of way that can be decoded by Fourier transform. This then produces an A-scan in much the same way that SD-OCT does and the A-scans can be assembled to create an image, a B-scan.

Remember that with SD-OCT, there is a fall off in sensitivity with increasing depth. There's also a fall off with swept-source OCT, but it's not much in terms of depth as compared to SD-OCT, so the images produced are different. We don't see the choroid as well with SD-OCT as we do with swept-source OCT. With swept-source OCT, we get good signal strength and thus good image quality in the vitreous and choroid in the same image (see Figure 1).

Another feature of swept-source OCT is that the light sources available generally operate in the 1 μ m domain at 1,050 nm, which is a longer wavelength than that used for SD-OCT, which is usually around 840 nm. This increase in wavelength penetrates tissue better, and with less scatter, so we are able to image deeper structures better. We should be able to penetrate media opacity such as cataract better as well. There is a reso-

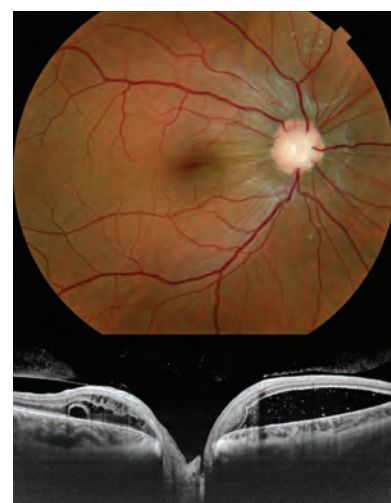

Figure 1. Fundus photo and DRI OCT image of a patient with Morning Glory Syndrome. Notice the highly detailed structures in the entire OCT image from top to bottom.

Photos courtesy Richard F. Spaide, MD

lution trade-off with longer center wavelengths, however.

These advances have all culminated into the first commercially available swept-source OCT, which took a lot of work and innovation on the part of Topcon to produce. The Deep Range Imaging (DRI) OCT-1 Atlantis[†] is fast, scanning at 100,000 A-scans per second, so we don't have to worry as much about eye motion artifacts. The instrument possesses a good ability to visualize information inside the vitreous. You can easily see three cortical vitreous pockets inside the vitreous and you can see great detail inside the retina, including the choroid and the sclera.

Consider the individual with a serous detachment. We had a patient whose optic nerve showed some unusual cupping and was a bit large compared to the other side, yet an optic nerve pit was not noticeable. We carefully scanned the optic disc with swept-source OCT and found that the patient actually had an occult optic nerve pit not visible by ophthalmoscopy. (See center image on cover for an example of an optic nerve pit.)

MYOPIA AND CHOROID THICKNESS

Myopes have relatively normal eye growth early in life before their eyes begin to expand in such a way that the sclera stretches and thins out. Actually, the dry weight of collagen in the sclera of a high myope is less than that in an emmetrope. The same holds true for the extracellular matrix. The diameter of the collagen fibers in high myopes are thinner than in em-

Q When you see changes or tears in the lamina cribrosa, does that cause the glaucoma damage, or is it the result of glaucoma damage? When you see changes in the choroid in myopia and changes in the sclera, is that cause or effect?

A In the first studies looking at choroid thickness, we could see that there was a correlation between thickness and the amount of myopia, an independent factor, and also a correlation with age. Both apparently influence—or at least predict—choroidal thickness.

If you look, for example, at a patient with staphyloma, the staphyloma increases in size and the choroid gets correspondingly thinner. So you wonder if there's some kind of feedback loop that exist in the choroid through the sclera that somehow affect the development of myopia. Myopia affects the choroid and maybe the choroid affects myopia.

We have known for decades that if we take an animal model and close their eye or give them a de-focused image at a young age, their eye will become myopic. Curiously, if you cut the optic nerve and do the same thing, the eye gets just as myopic. It's not influenced by the brain at all; it's straight from the eye. But if you de-focus the image to half of the eye, that half of the eye becomes myopic—and that's true even if you cut the optic nerve. So there's some local factors that apparently involve stimulation of the retina, realization of the image by the retina, that communicate through or by the choroid to the sclera. In myopia models, the sclera itself softens, the extracellular matrix decreases in weight, the collagen fibers start to remodel, the collagen gets thinner and the eye starts to expand and somehow this is communicated through the choroid.

As for the lamina cribrosa, eyes with glaucoma and eyes with high myopia with or maybe without glaucoma can develop tears in the lamina. A commonly known entity is to see a pseudo-pit of the optic nerve in late-stage glaucoma. This frequently is found to be caused by a tear in the lamina. The nerve fibers going through the lamina are subject to a variety of forces, and it is likely that these forces can change in the case of a tear. The consequence of this is not known at present because we haven't had a clinical way to detect the tears before.

metropes. Needless to say, quite a few unusual elements co-exist with this expansion of the eye. Although we don't know too much about the choroid in these patients, as a rule of thumb, the choroid generally looks about as thick as the retina and has a kind of cross-sectional look like a sponge. Generally, the bigger blood vessels are toward the outer part of the choroid. We have discovered that choroid thickness decreases with increasing myopia as well as from normal aging.

CONDITIONS OF THE MACULA, CHOROID AND SCLERA

We conducted a study of two patient populations—one in

New York and one in Japan—and interestingly, we found the same thing in both populations, independent of race: that the biggest predictor of visual acuity in high myopes who have no other abnormalities is the thickness of their choroid.¹ This is a bit of an unusual concept, as we typically think of people having relatively good visual acuity even in high myopia. But in reality, many patients with high myopia have somewhat decreased visual acuity; it's a highly prevalent problem.

We also found that some patients have what's called **dome-shaped macula (DSM)**, which is characterized by an abnormal convex macular contour within

the concavity of a posterior staphyloma (see Figure 2). Many theorize why this occurs. We looked at high myopes and found that there was some regional variations in the thickness of the sclera, which is unusual. And in some patients, this DSM may be a little bit protective. Some patients have myopic schisis except in the macula, where the DSM configuration has occurred. The sclera may almost act like a buckle to lead to a favorable outcome. Additionally, we discovered that patients with DSM can have fluid, and those patients generally don't have such a thin choroid.

Intrachoroidal cavitations (see Figure 3) occur in about five percent of high myopes. The sclera bulges backward in these patients to create the localized increase in choroidal thickness. When the tensile forces acting on the choroid exceed its structural strength, the cavity forms.

Age-related choroidal atrophy causes thinning of the choroid and is associated with tessellation in the fundus. Some peripapillary atrophy may be present as well, and we might expect to see these characteristics in high myopes, but they may also present in older patients. We have a biased population in our series, and it seems that




Figure 3. Intrachoroidal cavitation with retinal defect.

these patients are more likely to have glaucoma. And while fluorescein doesn't show up well, OCT does show that the choroid is extremely thin.

When we perform microperimetry on patients who have a relatively normal thickness choroid, they typically have good microperimetry scores. On the other hand, patients who have age-related choroidal atrophy typically have decreased microperimetry results. They may complain about not being able to drive at night or having a hard time reading menus in restaurants, which are real-world demonstrations of what microperimetry is showing us. Thinner choroids can result with worse vision in terms of visual function and microperimetry and can show up in everyday activities.

Central serous chorioretinopathy (CSC). In 1967, Gass wrote a paper that discussed what was then called central serous retinopathy. He changed the name to central serous choroidopathy because he thought people with this condition had abnormalities in their choroid, that it was

too permeable and that this hyperpermeability led to an elevation of the retinal pigment epithelium. He asserted that the fluid pushed with enough force to cause a defect in the retinal pigment epithelium and that the fluid lifted the retina as well. His claim caught our attention because if this is true, you would expect the choroid to be thicker.

In the mid-1990s, we were interested in indocyanine green (ICG) and we worked with Topcon in trying to develop ICG angiography. Some of the first papers I wrote about ICG angiography looked at hyperpermeability of the choroid in central serous patients.² That was 30 years after Gass thought there was hyperpermeability, but the ICG papers actually showed proof that there is hyperpermeability in the choroid and that it is very much thickened in patients with CSC.

In the past, we have used ICG angiography, but with OCT, we can find much of the same information without subjecting the patient to the angiography. OCT using techniques to aid visualization of deeper portions of the eye show the choroid is thicker in eyes with CSC. This is typically a bilateral, although sometimes asymmetrical, finding in that the fellow eye, even if uninvolved with CSC, can show a thicker choroid.

Laser photocoagulation will get rid of the subretinal fluid in central serous patients. We measured the choroid thickness in patients whom we treated with laser and found no change over time. Curiously, the choroid actually is thicker two days

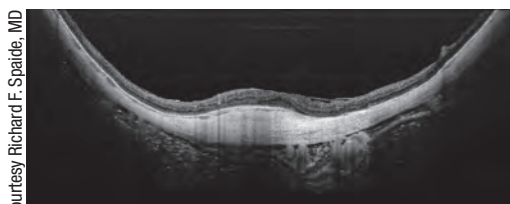


Figure 2. Dome-shaped macula in a highly myopic eye.

after performing photodynamic therapy (PDT), and there's also an increase in sub-retinal fluid. But after 28 days or so, the fluid dissipates and the choroid thins.

While we have seen laser-treated patients with central serous have recurrences, those who have undergone PDT usually don't often have recurrence of fluid.

BETTER TECHNOLOGY, BRIGHTER FUTURE

The deeper imaging capability of the DRI OCT-1 Atlantis allows us to see not only the retina and vitreous just as well as we could before (and in some ways better), but we can now also see the choroid, the sclera and the optic nerve in new ways. Consequently, we will have a better understanding of the diseases we commonly treat. It is likely this new technology will advance both our understanding of some ocular pathologies, and our capability to monitor treatment effects.



Dr. Spaide is in private practice at Vitreous-Retina-Macula Consultants of New York. His particular interests include retinal surgery, macular degeneration, macular holes, macular

pucker, diabetic retinopathy and intraocular inflammation.

Swept-source OCT in Glaucoma

A further look into the applications of this imaging modality.

Robert N. Weinreb, MD

Swept-source optical coherence tomography is a break-

through technology, and to the best of my knowledge, Topcon's Deep Range Imaging (DRI) OCT-1 Atlantis is the first commercial swept-source OCT for posterior imaging. It's also the fastest commercial OCT, with about 100,000 A-scans per second.

With a long 1,050-nm wavelength light source, it also can image the choroid. For evaluation of the optic nerve and parapapillary retina/choroid, it penetrates the choroid and the lamina deeper and also sometimes provides visibility of the sclera.

There are several advantages to swept-source OCT, including deeper penetration into the choroid and the sclera, uniform high sensitivity that allows visualization of the vitreous, the choroid and the lamina cribrosa in the same scan (see Figure 1), and also the sclera in many patients. The high speed reduces the affect of eye movements. In a disease such as glaucoma, where one is interested in quantitative measures, it's very important to be able to detect small changes and to have stable images. Also, higher speed reduces the effect of saccadic eye movements, and less light scattering improves results in eyes with cataracts. Additionally, automatic segmentation and a wide (12 mm x 9 mm) field scan allow you to visualize the

macula and the disc, along with the sclera and various layers of the retina in the same scan. The uniform sensitivity is key. You can visualize changes in the vitreous at the same time you are looking at deeper structures such as the choroid.

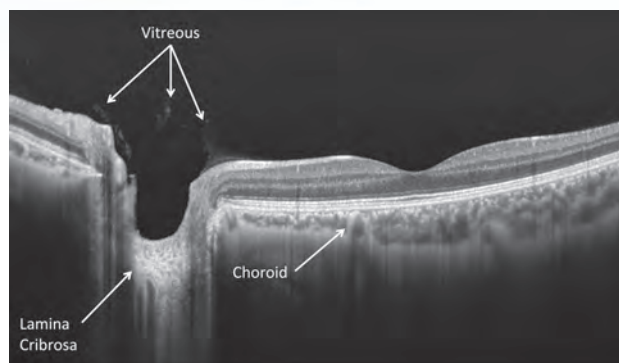


Photo courtesy Robert N. Weinreb, MD

Figure 1. One advantage of swept-source optical coherence tomography is that it allows visualization of the vitreous, the choroid and the lamina cribrosa in one scan.

IMAGING GOALS IN GLAUCOMATOUS EYES

With swept-source OCT, you can readily visualize the retinal and choroidal anatomy. The software that accompanies the technology allows you to view the various layers and the wide scan enables you to see both the macula and the optic disc simultaneously. There is no need to perform separate scans of the macula and the optic disc that is required with spectral-domain OCT. With swept-source OCT, you can quantitatively assess the thicknesses of various layers including the retinal nerve fiber layer (RNFL), the ganglion cell layer plus the inner plexiform layer, which consists of the dendrites of the retinal ganglion cells, and other layers including the inner and outer retinal layers as well as the choroid. You can see almost

anything within the retina and develop quantitative measures, not only for diagnosis, but also for monitoring the effects of your therapy and changes over time. Swept-source OCT also allows you to image the anterior segment and go from sulcus to sulcus with improved visualization, thanks to the penetration of the wavelength.

In glaucoma, we are most interested in the RNFL, the retinal ganglion cells and the inner plexiform layer. Using this technology, we can clearly map and delineate the ganglion cell complex, which includes the RNFL (the axons of the retinal ganglion cells), the ganglion cell layer (ganglion cell bodies) and the inner plexiform layer (the dendrites of the retinal ganglion cells). You can even map out the ganglion cell layer plus inner plexiform layer directly, without the RNFL, which provides a more precise determination of the integrity of the ganglion cells at that particular location (since RNFL contains axons from ganglion cells from distal parts of the retina).

As glaucoma progresses,

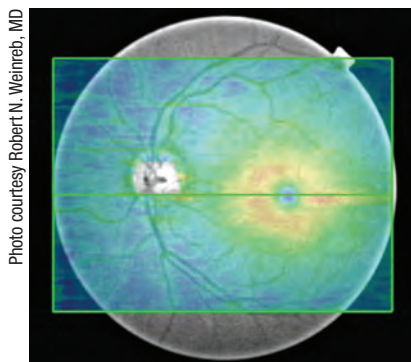


Figure 2. The “ganglion cell layer plus” is one of several thickness maps available from one scan. This is a scan of a normal patient.

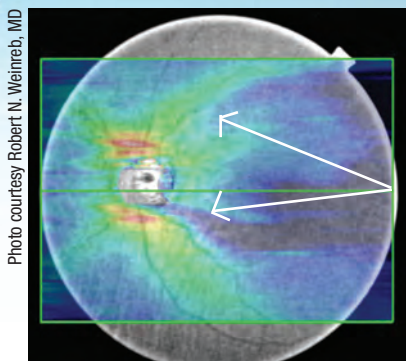


Figure 3. RNFL thinning (wedge defects) in a 66-year-old patient with a paracentral visual field defect.

there's an initial loss of dendrites. With loss of target-derived neurotrophic growth factors, the dendrites contract and then ultimately, there is loss of retinal ganglion cells and RNFL. You also can view the “ganglion cell layer plus” (see Figure 2), which is the retinal ganglion cells and the inner plexiform (i.e., the GCC without the RNFL). Because dendritic shrinkage is often the first structural change to the ganglion cell, inner plexiform thickness changes should be an early indicator of glaucoma.

With swept-source OCT—and the DRI OCT-1 Atlantis in particular—one can visualize the choroid as well. I believe this has considerable potential for diagnosing glaucoma, monitoring progression and also perhaps for use as a therapeutic target. Not only can you see the thickness of the RNFL, but also the area of the macula and how that changes. As you lose nerve fibers in absolute glaucoma, your RNFL still has a thickness comprised of glial cells, so when you use OCT to look at thickness, you never really reach zero

thickness. And I think that with swept-source OCT, we might be able to quantify these changes much better.

A NEW VIEW OF A PARACENTRAL VISUAL FIELD DEFECT

A 66-year-old patient from our clinic has a paracentral visual field defect. Changes in the intranasal area were observed on the pattern deviation as well as on the gray scale. Not surprisingly, a narrowed neuroretinal rim inferior temporally was visible when viewing this patient's optic disc. Additionally, some change in the RNFL in that area as well as a very fine disc hemorrhage was also noted.

Figure 3 shows the RNFL of this patient with the DRI OCT-1 Atlantis, revealing a broad RNFL defect. The advantage of a larger field is that, as you move away from the disc margin, you can see how the RNFL defect actually broadens and respects the horizontal meridian and goes up to the macular region. Changes were also noted in the paratemporal area as well as superior temporal, which correspond to the superior and inferior visual field defects, respectively. Changes were also evident right about the paramacular region, proving that glaucoma is not just disease of the RNFL around the optic disc, but very early in glaucoma, you can see changes in the macula.

An en face view of this patient reveals the lamina cribrosa pores (Figure 4). In a healthy patient, these pores typically have larger diameter in the superior and inferior areas, as well as thinner

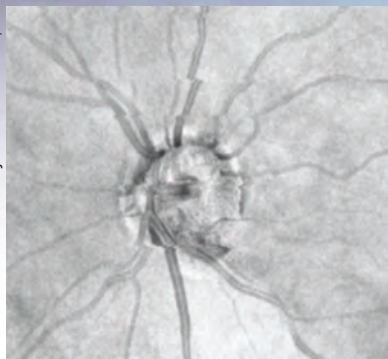


Figure 4. En face view of patient with a paracentral visual field defect.

walls, which might be the reason why we see RNFL defects occurring typically earliest in these regions. The larger pores and thinner walls may offer less structural support to the axons and may be more susceptible to glaucomatous changes. Being able to directly assess the integrity of the lamina cribrosa with swept-source OCT is an advantage and may lead to improvements in understanding, monitoring and treating glaucoma.

UP CLOSE AND PERSONAL WITH PRIMARY OPEN-ANGLE GLAUCOMA

Another 66-year-old patient from our clinic has bilateral

primary open-angle glaucoma with very significant visual field changes above the horizontal in the right eye and in the left eye. Thinning of the neuroretinal rim could be seen in the optic disc photographs, and using DRI OCT-1 Atlantis to image the RNFL, we began to detect changes such as the RNFL defect in Figures 5a and 5b, which is narrow in the area next to the optic disc and begins to broaden away from the disc, as is typical of a wedge-like defect. And in the area of the macula, you could also see changes in the ganglion cell layer. Macula and RNFL defects are detected very well with this instrument. Choroid thinning is also evident, though we don't yet know the significance of choroidal changes in glaucoma.

A BROADER REACH FOR SWEPT-SOURCE OCT

Swept-source OCT is a breakthrough technology that is very promising in glaucoma for detecting structural damage in the optic disc, the lamina cribrosa, the RNFL, the retinal ganglion cells, the inner plexiform layer and the ganglion cell

complex. It also allows visualization of lamina pores and the thickness of the choroid, and has faster speed and greater penetration than SD-OCT (clearly, though, further research is needed to understand the significance of the choroid and lamina changes). Looking at choroidal circulation vis-a-vis visual field defects with this kind of a modality may be predictive of where defects will occur.

Dr. Weinreb is Distinguished Professor of Ophthalmology, Chair of the Department of Ophthalmology and Director, Shiley Eye Center at the University of California, San Diego.



Endpoint-managed Laser Retinal Photocoagulation

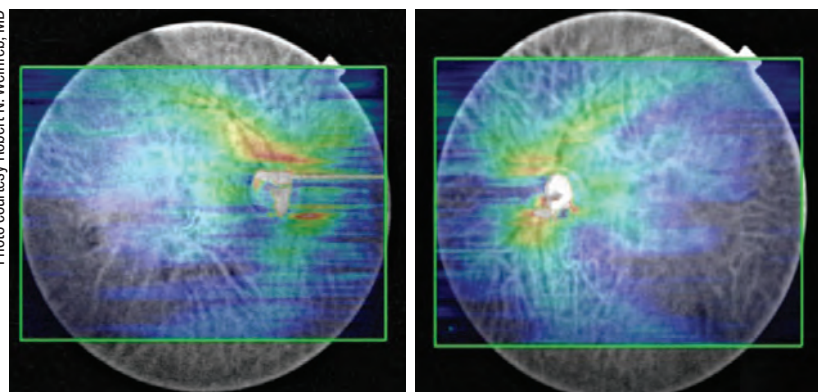
See how this laser treatment method fits into the retina world.

Pravin U. Dugel, MD

A potential exists for redefining laser photocoagulation in a manner that would be useful in both retina and glaucoma patients. For the purpose of this discussion, I am only going to discuss the applications for treating retinal disease, but the extrapolation from retina to glaucoma and other areas is easily made.

LASER PHOTOCOAGULATION IN RETINA

At this point, physicians may ask, "Why even talk about laser photocoagulation in retina? Isn't this a world of anti-vascular endothelial growth fac-



Figures 5a (left) and 5b (right). Retinal nerve fiber layer defect noted with the DRI OCT-1 Atlantis.

tors (anti-VEGFs)?” Using Medicare data and several other databases, we have recently looked at the use of anti-VEGF injections in a number of chronic diseases in the first year following diagnosis.

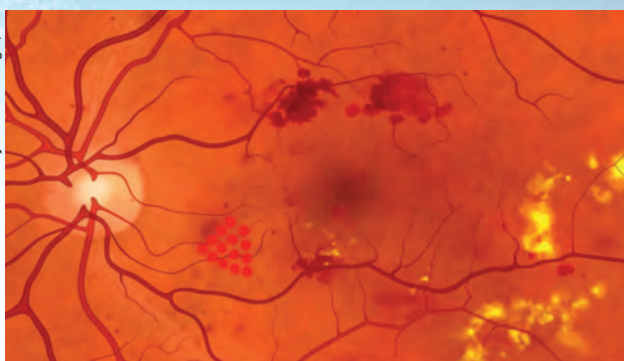
In neovascular macular degeneration, guidelines from the ANCHOR³ and MARINA⁴ studies recommend approximately 12 injections in the first year following diagnosis. In reality, the average number of ranibizumab (Lucentis) injections is 5.8, less than half the recommended frequency. Similarly, bevacizumab (Avastin) averages 4.5 injections in the first year. Clearly, we are vastly undertreating our patients, whether we use ranibizumab or bevacizumab.

In the case of branch retinal vein occlusion, the BRAVO trial showed us that we should be injecting approximately nine times in the first year,⁵ but in reality, we are only injecting 2.8 times. In the case of central retinal vein occlusion, we should be injecting approximately nine times,⁶ but we are injecting an average of 3.1 times.

What about diabetic macular edema (DME)? According to the Diabetic Retinopathy Clinical Research Network (DRCRnet) Protocol I study, we should be injecting approximately nine times in the first year of diagnosis, but in reality, we are only injecting an average of 2.9 times in the first year.⁷

There is clearly an enormous

Photo courtesy Pravin U. Dugel, MD



Topcon's PASCAL Photocoagulator is a fully integrated pattern scanning system that allows the rapid delivery of 532 nm laser pulses in a predetermined sequence.

disconnect between what we should be doing according to the randomized clinical trials and publications and what we are actually doing in practice. Have we reached a threshold for treatment burden that we simply cannot get beyond? I think our treatment model for these chronic diseases is simply not sustainable.

How has this affected efficacy? If we look at all the recent anti-VEGF DME trials, the relationship between the number of injections and visual acuity is very strong and decidedly linear. The more injections, the better the visual outcome. Therefore, given this disconnect between randomized clinical trials and community practice, the majority of our patients must not be achieving the visual results reported in the randomized clinical trials because we are vastly undertreating them.

DOES LASER HAVE A PLACE?

It would seem that laser photocoagulation would have an important place in the treatment of DME, as it increases efficacy and reduces treatment

burden. However, laser photocoagulation has a bad reputation with retina specialists because of one archaic study, the Early Treatment Diabetic Retinopathy Study (ETDRS).⁸ We quote this study as proof that laser photocoagulation does not improve vision. Indeed, in this study, less than 10 percent of patients improved three lines or

more. However, it is important to actually examine the details of this study, rather than simply regurgitate the headlines.

In this study, 85 percent of patients could not mathematically improve three lines because they had good vision upon enrollment. In other words, there was a “ceiling effect” for visual acuity improvement in 85 percent of the enrolled patients. If we look at the patients who *could* mathematically improve three lines or more vision, 40 percent achieved that goal. In other words, if we only look at patients who are able to improve three lines or more of vision, 40 percent achieved that endpoint. In my opinion, that is an impressive improvement. It is important for retina specialists to understand the details of this study and to stop perpetuating the myth.

Traditional laser photocoagulation is destructive. Unfortunately, in some patients with intense laser photocoagulation, the destructive effects increase over time. This is a phenomenon known as atrophic creep.

A decade or so ago, it was thought that intense laser photocoagulation was required to achieve success. Unfortunately, in years following, patients who were successfully treated initially sometimes lost vision as the laser photocoagulation scar continued to enlarge due to atrophic creep. This is a real phenomenon and has added to traditional photodestructive laser photocoagulation's bad reputation.

Topcon Medical Laser Systems has developed a new laser-based treatment method named Endpoint Management for its PASCAL Photocoagulator, which is known for being able to treat with fixed patterns in a fast and efficient manner. Endpoint Management now allows the PASCAL laser to treat more precisely with minimal photodestruction. The marriage of these two systems allows for greater efficiency and accuracy. The immediate result is greater patient comfort with decreased pain and, hopefully, better efficacy. The decreased level of energy should help avoid atrophic creep. This system has taught us to look at laser photocoagulation in a completely different light. By controlling two important variables: duration and power, we are able to minimize collateral laser destruction known by scientists as thermal laser bloom and known by clinicians as atrophic creep.

Stanford's Daniel Palanker was also able to show that barely visible laser photocoagulation creates very small gaps in the RPE layer.⁹ In a short period of time, the neighbor-

Q If using laser to get rid of macular edema, what areas do you target, where do you put your endpoints and what fields are you treating?

A Laser photocoagulation marries the convenience and precision of the PASCAL grid patterns with the accuracy of the Endpoint Management system. Physicians first need to choose the appropriate pattern for the treatment area. Then, test laser spots may be used to find the appropriate power and duration to create a burn that is barely visible. This will be the landmark treatment spot at 100 percent. Thereafter, the physician can select any percentage of that landmark spot to deliver laser treatment. In other words, the desired percentage may be 75 percent, 50 percent or 30 percent. Once the percentage is selected, the proprietary mathematical formulation will use the two variables (duration and power) to precisely deliver the desired percentage in the pattern area. The edges of the pattern will remain at 100 percent so that the physician will know that treatment has been delivered in the desired pattern.

It is interesting to note that since this treatment is a photostimulation rather than photodestruction, and since animal studies have shown that photoreceptor cells are not damaged, my Brazilian colleagues who have a lot of experience using the Endpoint Management system have no qualms about treating over the fovea in patients with severe diabetic macular edema and poor vision. Their experience has given them enough confidence that photoreceptor cells will not be destroyed using this system. I have seen their results and they are very impressive. Their results have encouraged me to begin a scientific inquiry in the United States.

ing RPE, because it is not damaged, is able to slide over that gap and restore the photoreceptor cells. In a few weeks, the retina appears completely normal, as though laser photocoagulation had not been done at all. Functionally, that area returns to normal.

If these synaptic connections could actually be rewired, perhaps the amount of laser photocoagulation needed would be minimal. Animal studies show that decreasing laser treatment to a point of being barely visible achieved the desired effect while allowing photoreceptor cells to maintain anatomical and functional integrity. The significance in this is in being able to achieve efficacy without causing destruction. However, there is a real logistic problem: If we treat at levels that are not visible, how do we know what we are treating or if we are even treating it properly?

INTRODUCING ENDPOINT MANAGEMENT

Endpoint Management is a new laser treatment paradigm that uses a mathematical model to precisely control two variables: power and duration. The goal is to treat at very low laser levels to minimize damage while maintaining clinical efficacy. The idea is to set the treatment level to very light or barely visible burn, so that with Endpoint Management, the percentage of energy delivered can be very precisely down-regulated using the very light or barely visible burn as the 100 percent level. For example, one may choose a 75 percent level for Endpoint Management, which delivers 75 percent of the barely visible spot. The energy delivered is controlled by the software that automatically adjusts the power and duration according to a proprietary mathematical formula.

The solution is very elegant

because it marries the efficiency of the PASCAL Photocoagulator with the accuracy of the Endpoint Management system. In order to make sure that treatment has been delivered to the proper place, the edges of the pattern remain at the higher—or barely—visible level. This is accomplished by using the Landmark feature, which sets the edges of the pattern at the 100 percent (barely visible) level. This way, the edges of the treatment pattern can be seen, giving the physician the confidence that the desired treatment has been delivered.

At 30 percent, it seems as though there is no disruption of the RPE or any retinal layers, so we're not causing any destruction; we are actually stimulating the RPE cells. The accuracy and precision of targeting RPE cells has clearly been taken to a new level; therefore, our nomenclature will need to reflect this. The words "photodestruction" or "photocoagulation" may not be appropriate. Our new nomenclature may be "RPE photostimulation."

We are currently in the process of conducting a small, 10-patient, Phase I pilot study and as with any pilot study, there are only two goals: safety and biological signal. Also, with any pilot study, patients with very severe disease have been recruited. We have based severity, not only in terms of visual acuity, but also in terms of the OCT image. This leads to another question: is OCT a good surrogate to determine clinical efficacy in DME? In many DME studies, a definite disconnect between visual acuity and OCT has been shown.

While the OCT may be a good barometer for VEGF in addition, it may not be a good barometer for numerous other chemical factors that are involved in the DME process.

With that in mind, consider the interim results of this small pilot study. At this point, seven out of nine patients have demonstrated improved vision and these are patients who have such severe disease that I did not expect any vision improvement.

NEW POSSIBILITIES

We are at a critical juncture in how we perceive laser photocoagulation. I believe that laser treatment is a particularly important and necessary tool in this day and age of anti-VEGF treatment, where there is a huge disconnect between the randomized clinical trial results and community practice. Therefore, there is also a significant and growing disconnect between the vision results our patients should be getting and the results they are actually getting.

To decrease this treatment burden, combination therapy must be investigated. Laser treatment is complimentary to anti-VEGF treatment. The two modalities are not mutually exclusive, but rather synergistic. With Endpoint Management, we now have an elegant, efficient and accurate laser treatment delivery system that completely redefines this field. This redefinition is so profound that the terms "laser photocoagulation" and "laser photodestruction" may be archaic and should be replaced by the term "laser photostimulation."

Dr. Dugel is managing partner of Retinal Consultants of Arizona and founding member of the Spectra Eye Institute. He is also clinical associate professor, Doheny Eye Institute, Keck School of Medicine, University of Southern California.



**Topcon's DRI OCT-1 Atlantis is currently available for sale outside the United States and is currently unavailable in the United States.*

REFERENCES

1. Nishida Y, Fujiwara T, Imamura Y, et al. Choroidal thickness and visual acuity in highly myopic eyes. *Retina*. 2012;32:1229-36.
2. Spaide RF, Hall L, Haas A, et al. Indocyanine green videoangiography of older adults with central serous chorioretinopathy. *Retina*. 1996;16:203-13.
3. Brown DM, Kaiser PK, Michels M, et al; for the ANCHOR Study Group. Ranibizumab versus verteporfin for neovascular age-related macular degeneration. *N Engl J Med*. 2006;355(14):1432-1444.
4. Rosenfeld PJ, Brown DM, Heier JS, et al; for the MARINA Study Group. Ranibizumab for neovascular age-related macular degeneration. *N Engl J Med*. 2006;355(14):1419-1431.
5. Campochiaro PA, Heier JS, Feiner L, et al. BRAVO Investigators. Ranibizumab for macular edema following branch retinal vein occlusion: six-month primary end point results of a phase III study. *Ophthalmology*. 2010;117:1102-1112.
6. Brown DM, Campochiaro PA, Singh RP, et al. CRUISE Investigators. Ranibizumab for macular edema following central retinal vein occlusion: six-month primary end point results of a phase III study. *Ophthalmology*. 2012;117:1124-1133.
7. Slater D, Yeh WS, Chia YJ, Kowalski JW. Real-world utilization of intravitreal anti-vascular endothelial growth factor (anti-VEGF) agents in common retinal diseases. Poster presentation at the Academy of Managed Care Pharmacy Educational Conference, Atlanta, Georgia, October 19-21, 2011.
8. Photocoagulation for diabetic macular edema. Early Treatment Diabetic Retinopathy Study Report Number 1. *Arch Ophthalmol*. 1985; 103(2):1796-1806.
9. Palanker D, Lavinsky D, Blumenkranz MS, Marcellino G. The impact of pulse duration and burn grade on size of retinal photocoagulation lesion: implications for pattern density. *Retina*. 2011;31(8):1664-9.



Sponsored by

REVIEW[®]
of Ophthalmology

Supported by

 **TOPCON**[®]
CONNECTING VISIONS