

Swept-source OCT

Wide-field simultaneous choroid, retina, and vitreous visualization.

**BY ZOFIA MICHALEWSKA, MD, PhD; JANUSZ MICHALEWSKI, MD, PhD;
AND JERZY NAWROCKI, MD, PhD**

During the past decade we have witnessed tremendous development in visualization techniques for the posterior segment of the eye. Time-domain optical coherence tomography (TD-OCT) impressed retina specialists but was soon left in the shade by spectral-domain OCT (SD-OCT), which offered higher resolution (1 μm to 3 μm axial resolution with SD-OCT vs 10 μm with TD-OCT) and 3-D imaging possibilities. Retinal imaging in vivo could be correlated with histopathologic findings. It was not long, however, before retina specialists wanted to see deeper into the eye to visualize the choroid.

Retina function depends on nourishment and oxygen derived from the choroidal vasculature. Many diseases affecting the macula, such as age-related macular degeneration (AMD), polypoidal choroidal vasculopathy (PCV), and central serous chorioretinopathy (CSC) have been reported to be secondary to or correlated with choroidal dysfunction.^{1,2} Dilatation of choroidal vessels may lead to increased choroidal thickness, which further results in a rise in hydrostatic pressure and increased vessel permeability. On the other hand, choroidal thinning leads to insufficient nourishment of the retina, resulting in retinal pigment epithelium (RPE) degeneration and in photoreceptor layer loss. Until recently, the function of the choroid could be visualized only en face, by indocyanine angiography.

Knowing that the resolution of OCT is sharpest near to the zero-delay line, Spaide³ discovered that by inverting the SD-OCT image, thus approximating the choroid to the zero-delay line, choroidal visualization was possible (Figure 1).

Swept-source OCT (SS-OCT; DRI-OCT, Topcon Japan) is the latest milestone in retinal and choroidal imaging. To overcome scattering by the RPE, which disabled visualization of deeper lying structures, a longer wavelength was adopted for this machine (1050 nm vs 840 nm in SD-OCT), and photodetectors instead of CCD cameras led to a further increase in resolution (1 μm). The scan speed in swept-source instruments is twice

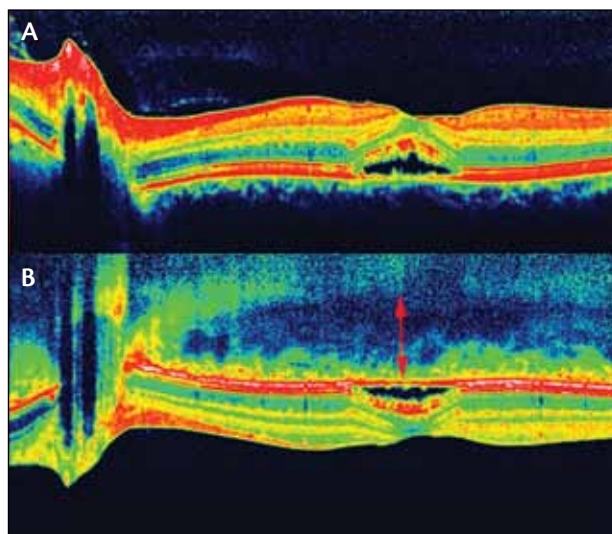


Figure 1. SD-OCT of active central serous chorioretinopathy (A). EDI-OCT of the same eye (B) showing increased choroidal thickness. The image is inverted to demonstrate the manner in which the choroid is visualized with SD-OCT. Knowing that best resolution is obtained with this device near the zero-delay line, choroidal images are obtained by approximating the eye to this line, which results in an inverted image. The software available on the Spectralis reinverts the image to present it in standard fashion.

that of SD-OCT devices (100 000 A-scans/sec compared with 50 000 A-scans/sec), enabling faster acquisition of B-scans, thus allowing us to obtain widefield B-scans (12 mm vs 6–9 mm with conventional SD-OCT) and more accurate 3-D imaging of the vitreous, retina, and choroid (Figure 2). Wide scans make it possible to present the optic nerve and macula on the same scan. Simultaneous high-quality visualization of the vitreous, retina, and choroid is possible. Choroidal layers that are hardly distinguishable in conventional SD-OCT become visible. The new SS-OCT confirms earlier histologic data: the structure of the choroid consists of multiple layers going from the innermost Bruch membrane to the

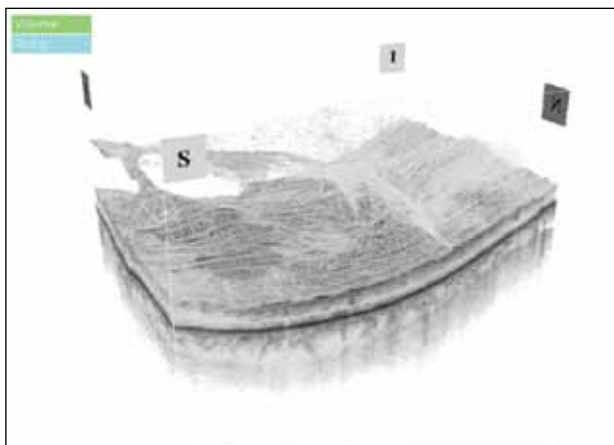


Figure 2. 3-D visualization of the vitreous, retina and choroid in SS-OCT.

choriocapillaris, Sattler layer (layer of medium diameter blood vessels), Haller layer (outermost layer of the choroid consisting of larger diameter blood vessels), and lamina suprachoroidea (Figure 3).⁴ Usually behind the lamina suprachoroidea—a hyperreflective line indicating the choroidoscleral boundary—sclera of diminishing reflectivity can be seen. Arteries and vessels running through the sclera may also be visualized. Additionally, in some eyes, a hyperreflective linear structure between the lamina suprachoroidea and sclera has been visualized by our group and judged to be the suprachoroidal space (Figure 4).⁵ Although this hypothetical space had not been visualized by conventional techniques previously, except in eyes with choroidal effusion, new surgical and pharmacologic techniques are currently being developed to introduce drugs into this space. Thus visualization would appear to be of great importance in identifying the effects of these interventions.

Using a longer wavelength also overcomes cataractous lens opacities and allows visualization of the macula in eyes with disabled fundus view (Figure 5). This may enhance the ability to identify patients who will need additional vitreoretinal service besides simple cataract surgery.

Swept-source OCT enables us to precisely visualize choroidal structure, which may enhance our knowledge of retinal diseases. It must be considered that, unlike retinal thickness, choroidal thickness is not as unchangeable. First, if choroidal thickness is to be compared in the same patient, measurements should be carried out at about the same time of day. The choroid is thickest in the early morning hours and at night, and is at its average thickness in the afternoon. Other factors responsible for changes of choroidal thickness are age, refractive error, and axial length. Older individuals and myopic eyes therefore have thinner choroids than

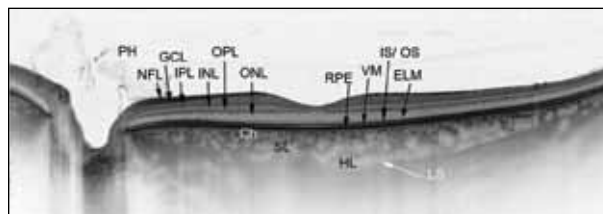


Figure 3. SS-OCT 12-mm scan using the DRI-OCT visualizes the optic nerve head and macula in a healthy eye. (PH: posterior hyaloid; NFL: nerve fiber layer; GCL: ganglion cell layer; IPL: inner plexiform layer; INL: inner nuclear layer; OPL: outer plexiform layer; ONL: outer nuclear layer; ELM: external limiting membrane; IS: ellipsoid inner segments of photoreceptors, VM: Voerhoff membrane; RPE: retinal pigment epithelium; Ch: choriocapillaries; SL: Sattler layer; HL: Haller layer; LS: lamina suprachoroidea)

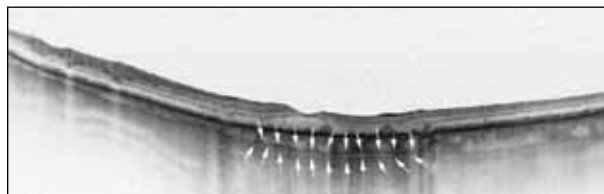

Figure 4. SS-OCT of an eye with drusen. White arrows indicate suprachoroidal space.

younger and emmetropic patients. This must be taken into consideration when analyzing the role of the choroid in macular and retinal diseases.

It has been suggested that the choroid thins in cases of neovascular AMD and thickens in CSC. However, there are many diseases in which the role of the choroid is more elusive.

ARE VITREORETINAL INTERFACE DISEASES ASSOCIATED WITH THE VITREORETINAL INTERFACE?

Traditionally, macular holes, epiretinal membranes (ERMs), and vitreomacular traction (VMT) syndrome have all been described as vitreoretinal interface diseases. It is generally accepted that vitreoretinal traction on the macula may lead to full-thickness macular hole (FTMH) formation, and it has been reported that the force may be exerted through cortical vitreous onto Müller cell cones and that elevation of the photoreceptor layer may precede FTMH formation. This theory, however, does not explain the rare event of FTMH formation in previously vitrectomized eyes or reopenings of previously closed macular holes. Recent enhanced-depth imaging OCT (EDI-OCT; Spectralis, Heidelberg Engineering) studies suggest an additional role of the choroid in the etiopathogenesis of these dis-

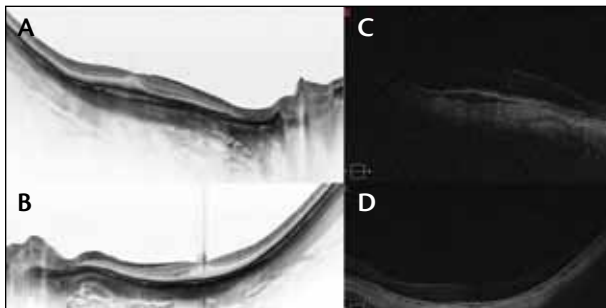


Figure 5. Right and left eye of a patient with cataract imaged with SS-OCT (A and B). Despite the poor fundus view on indirect ophthalmoscopy, SS-OCT enables exact visualization of the posterior pole. Right and left eyes of the same patient imaged with SD-OCT (C and D). Poor scan quality is due to cataract, which also impairs fundus view in ophthalmoscopy.

eases. Several authors have described reduced choroidal thickness in eyes with FTMHs, as well as in unaffected fellow eyes, when compared with healthy controls.^{6,7} These authors suggested that reduced choroidal thickness may be primary to FTMH formation. In the fovea, retina vessels are lacking, and it is fully supplied with oxygen and blood by the underlying choroid. Thus, a theoretically reduced blood flow in the area of the fovea may be a cause of macular hole formation. Other authors argue with this data, demonstrating that choroidal thickness is not affected by the presence of macular holes.⁸ These differing opinions may be due to the fact that EDI-OCT does not enable automated segmentation of the choroid and that only manual measurements at certain points are possible. Additionally, the choroidoscleral boundary may be difficult to estimate in some cases. SS-OCT performed in our patients did not demonstrate any difference in choroidal thickness between affected, fellow, and healthy eyes in a group of 89 eyes. The differences in data may also be due to possible different etiopathogenesis of the disease that we are used to referring to as idiopathic macular hole. It cannot be excluded that, even if in most cases VMT is the cause of FTMH formation, in some it may be associated with thinning of the choroid. Perhaps in the future idiopathic macular holes might be reclassified as macular holes associated with VMT and macular holes associated with thinner choroid; maybe both theories are probable. Further studies to elucidate this, however, are needed.

We performed a study on choroidal thickness in idiopathic ERM. It is generally believed that tangential traction provoked by ERM and internal limiting membrane is the cause of the progression of the disease. In 16 patients we observed on SS-OCT a general trend

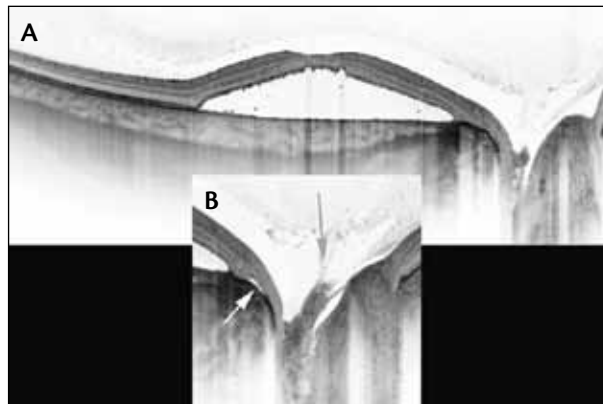


Figure 6. Optic disc pit associated maculopathy viewed with SS-OCT (A). Enlarged fragment of the upper image (B). Grey arrow: vitreous traction on the optic nerve. White arrow: possible intraretinal fluid flow from the optic nerve to the subretinal space.

SS-OCT performed in our patients did not demonstrate any difference in choroidal thickness between affected, fellow, and healthy eyes in a group of 89 eyes.

that choroidal thickness is increased when compared with normal age- and refractive-error-matched subjects. Here we might also ask whether the choroid is thickened because in most ERM cases foveal thickness is increased and thus perhaps a greater blood and oxygen supply is needed, or whether the thickening of the fovea is somehow a result of thickening of the choroid.

DEEP INTO THE OPTIC NERVE

It has been suspected that glaucomatous neuropathy of the optic nerve may be somehow associated with microstructural changes of the optic nerve. The lamina cribrosa is a mesh-like part of the optic nerve head through which the retinal ganglion cell axons and retinal blood vessels pass. Axonal damage, resulting in glaucomatous visual field loss, takes place primarily at the level of the lamina cribrosa. EDI-OCT demonstrated that the lamina cribrosa is visibly thinner in eyes with normal-tension glaucoma when compared with normal subjects.⁹ SS-OCT has presented evidence that those defects are associated with longer axial length and coexisting hemorrhages at the optic nerve.¹⁰ Additionally, SS-OCT enabled visualization of acquired

(Continued on page 56)

(Continued from page 52)

optic disc pits in about 16% of highly myopic patients.¹¹ With SD-OCT and other techniques, it was very difficult to estimate the fine details of optic disc structure, particularly when deeply excavated as in high myopia or in optic disc pit associated maculopathy.

SS-OCT has enabled the identification of those details. It may also add some knowledge in regard to the way fluid passes through the optic nerve into the sub- and intraretinal space in maculopathy associated with optic disc pits (Figure 6). ■

Zofia Michalewska, MD, PhD;
Janusz Michalewski, MD, PhD; and
Professor Jerzy Nawrocki, MD, PhD,
are with Klinika Okulistyczna „Jasne
Blonia” in Lodz, Poland. The authors
report no relevant financial relationships. They
can be reached at +48 42 6368282; or fax:
+48 42 6110505. Dr. Michalewska may be
reached at zosia_n@yahoo.com;
Dr. Michalewski may be reached at
shadowell@wp.pl; and Prof. Nawrocki may
be reached at jerzy_n@poczta.onet.pl.



1. Chung SE, Kang SW, Lee JH, Kim YT. Choroidal thickness in polypoidal choroidal vasculopathy and exudative age-related macular degeneration. *Ophthalmology*. 2011;118:840-845.
2. Maruko I, Iida T, Sugano Y, et al. Subfoveal choroidal thickness in fellow eyes of patients with central serous chorioretinopathy. *Retina*. 2011;31:1603-1608.
3. Spaide RF, Koizumi H, Pozzoni MC. Enhanced depth imaging spectral-domain optical coherence tomography. *Am J Ophthalmol*. 2008;146:496-500.
4. Michalewska Z, Michalewski J, Nawrocki J. Going deeper and going wider. *Retinal Physician*. 2013;3:42-48.
5. Michalewska Z, Michalewski J, Nawrocka Z, Dulczewska-Cichecka K, Nawrocki J. Lamina suprachoroidea and suprachoroidea space delineating the outer margin of the choroid in swept-source OCT. *Retina*. 2013 [in review].
6. Reibaldi M, Boscia F, Avitabile T, Uva MG, Russo V, Zagari M, Bonfiglio V, Reibaldi A, Longo A. Enhanced depth imaging optical coherence tomography of the choroid in idiopathic macular hole: A cross-sectional prospective study. *Am J Ophthalmol*. 2011;151:112-117.
7. Zeng J, Li J, Liu R, Chen X, Pan J, Tang S, Ding X. Choroidal thickness in both eyes of patients with unilateral idiopathic macular hole. *Ophthalmology*. 2012;119:2328-2333.
8. Schaal KB, Pollithy S, Dithmar S. Is choroidal thickness of importance in idiopathic macular hole? *Ophthalmology*. 2012;109(4):364-368.
9. Park HY, Jeon SH, Park CK. Enhanced depth imaging detects lamina cribrosa thickness differences in normal tension glaucoma and primary open-angle glaucoma. *Ophthalmology*. 2012;119:10-20.
10. Takayama K, Hangai M, Kimura Y, Morooka S, Nukada M, Akagi T, Ikeda HO, Matsumoto A, Yoshimura N. Three-dimensional imaging of lamina cribrosa defects in glaucoma using swept-source optical coherence tomography. *Invest Ophthalmol Vis Sci*. 2013;4:4798-4807.
11. Ohno-Matsui K, Akiba M, Moriyama M, Shimada N, Ishibashi T, Tokoro T, Spaide RF. Acquired optic nerve and peripapillary pits in pathologic myopia. *Ophthalmology*. 2012;119:1685-1692.

SHARE YOUR FEEDBACK

Would you like to comment on an author's article? Do you have an article topic to suggest?

We are interested in your feedback.

Please e-mail us at letters@bmctoday.com with any thoughts or questions you have regarding this publication.