

# Clinical Experience With Multispot Yellow 577-nm Laser

An important advancement in PRP treatment

SÉBASTIEN GUIGOU, MD • MARC CASSIAN, MD • ERIC PARRAT, MD

Retinal laser photocoagulation has been the mainstay of treatment for various retinal and macular diseases (eg, proliferative diabetic retinopathy, diabetic macular edema, retinal vein occlusions, and retinal tears) for many years. In addition, the quest for better visual outcomes and the minimization of side effects has resulted in the development of new, improved photocoagulation systems.<sup>1</sup>

These systems have been designed to optimize parameters such as wavelengths, energy levels, spot size, and pulse duration, which are essential for accurately targeting retinal tissue and for preventing side effects.<sup>1</sup>

Until relatively recently, the laser procedure was performed one burn at a time, with long duration (100-200 ms) and low power (200-400 mW). Over the past decade, a multispot modality for retinal photocoagulation emerged, with the laser delivering multiple, uniform laser burns simultaneously in a variety of patterns with a 532-nm wavelength.<sup>2</sup> As a result, the parameters improved, with shorter duration (10-20 ms) and more power (from 300 mW to greater than 600 mW).

One of the newest generation lasers is the Supra Scan 577 (Quanel Medical, Cournon d'Auvergne, France), which combines 577-nm yellow wavelength multispot delivery mode and the subthreshold micropulse mode.

## THE 577-NM YELLOW LASER

The 577-nm wavelength true yellow laser is not actually a new addition to the therapeutic armamentarium in ophthalmology; it was introduced more than 20 years ago for

Sébastien Guigou, MD, and Marc Cassian, MD, practice at Centre Hospitalier Henri Duffaut in Avignon, France. Eric Parrat, MD, practices at Clinique Les Eaux Claires in Baie-Mahault, Guadeloupe. Drs. Guigou and Cassian are consultants to Quanel Medical. Dr. Parrat reports no financial interests. Dr. Parrat's e-mail address is dr.parrat@orange.fr.

the treatment of diabetic retinopathy. At that time, it was a favored wavelength among retina specialists.

Unavailable for an entire decade for technological reasons, it was reintroduced in ophthalmology a couple of years ago. However, it was not until the emergence of the multispot treatment technique that it became a real alternative to 532-nm laser.

The advantages of the 577-nm laser are better penetration through cataracts, a moderate power level, and improved patient comfort.

The advantages of the 577-nm-wavelength laser are near-zero absorption by xanthophyll (macular pigment), excellent combined absorption by melanin and oxyhemoglobin, better penetration through cataracts, a moderate power level, and improved patient comfort (**Figure 1, page 30**).

The advantages of the multispot treatment technique include:

- the introduction of patterns so that several spots can be applied with a single pedal action with a calibrated spacing between each impact; and

- the combination of short exposure time with a higher energy level, resulting in shallower and narrower scars of the pigment epithelium.

Indeed, with the Supra Scan 577-nm, the spots are delivered faster, with a duration ranging from 10 to 20 ms, as opposed to 100 to 200 ms with traditional single-spot lasers. On the one hand, multispot lasers need higher power settings compared with traditional single-spot lasers, but on the other hand, multispot lasers require less exposure time.

Hence, the fluence is significantly reduced (power level x time/spot size): 6-7 J/cm<sup>2</sup> vs 47 J/cm<sup>2</sup> (300 mW/400 μm/0.2 s), but multispot and traditional single-spot lasers have shown similar regression of retinopathy.<sup>3</sup>

In this article, we share our preliminary clinical experience with the multispot yellow 577-nm laser at centers in Avignon, France (Drs. Guigou and Cassian), and Baie-Mahault, Guadeloupe (Dr. Parrat).

## STUDY 1

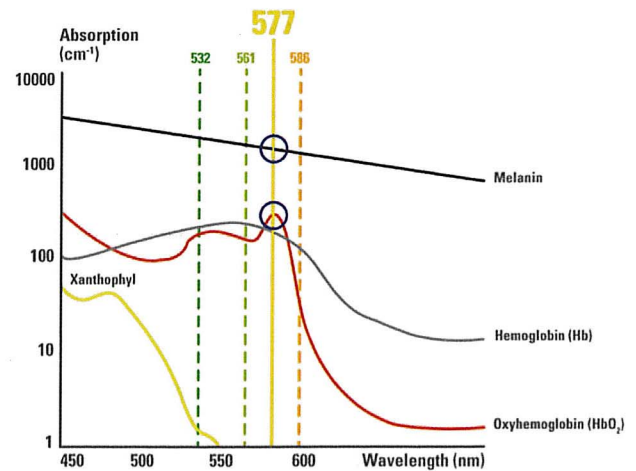
This was a pilot study of consecutive patients who underwent laser photocoagulation in the ophthalmology department at Centre Hospitalier Henri Duffaut Avignon, France, between May and July 2013. Consecutive patients who required panretinal photocoagulation (first or refilling procedures) were included. The following laser parameters were studied: power, duration, pattern, spacing, number of burns for each session, and total time.

A visual analog scale (VAS) was used to evaluate patients' pain perception (0 = no pain; 10 = worst pain ever experienced). We also noted the need for peribulbar anesthesia. Glare perception was assessed in the same way. The patients completed both scales after the procedure. Similarly, the surgeon's evaluation of the procedure was measured on a scale from 0 (difficult) to 10 (easy).

After we placed topical anesthetic drops in both eyes, we used a widefield contact lens (QuadrAspheric, Volk Optical, Inc., Mentor, OH) to offer the best stabilization of the ocular globe and lids. With the multispot Supra Scan 577-laser, we usually performed PRP in three concentric procedures with the same power burns, rather than the classic six radial areas. We did this to well manage the power level and the shape of the area treated (**Figure 2**).

Initially, the operator chose a 400-μm width (200 μm x 2) and 10- to 20-ms duration. Then, the operator adjusted the power to achieve grade 3 bleaching of the retina (medium gray spot). For PRP, 3 x 3 or 4 x 4 arrays were the most commonly used (**Figure 3**).

During the study period, we performed 27 procedures in 16 men and 11 women with a mean age of 67 years.



**Figure 1. Absorption of different laser wavelengths by various ocular pigments.**

Thirteen patients were phakic and 14 were pseudophakic; six patients showed dense cataracts (grade >3). Of 27 procedures, 20 (74%) were for PDR, five (18%) for central retinal vein occlusion, one for branch retinal artery occlusion, and one for ocular ischemic syndrome. Nine patients underwent treatment for the first time, while 18 underwent retreatment. No procedures required peribulbar anesthesia.

We used a mean power of 435 mW (250-675) for a mean duration of 17 ms (10-20 ms). The operators chose the 3 x 3 or 4 x 4 array, with a spacing of 0.5-0.75; the power had to be reduced, and the spacing had to be increased when treating the peripheral retina to avoid confluent burns or pain.

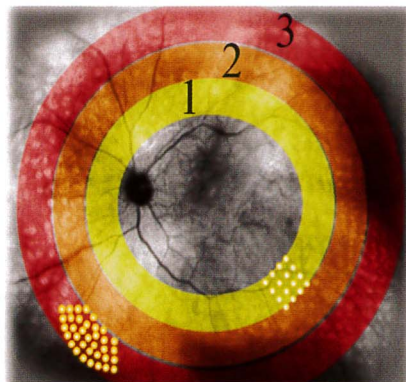
For the 14 patients who achieved complete PRP during the study, we observed regression of neovascularization at their final follow-up visits (**Figure 4, page 32**). No patients required further laser treatment.

The mean number of burns was 733 (475-1,200) per session, and the average duration of a session was seven minutes, 42 seconds (three to 15 minutes), corresponding to 58 seconds per 100 burns (32-96) on a normalized scale.

The mean CRT was 410 μm (290-800) at the first visit and 422 μm (280-810) at the final visit. Among the three patients in whom we conducted PRP in a single session, mean CRT was 380 μm at the first visit and 370 μm one month later. No complications, such as exudative retinal or choroidal detachment, occurred in those patients.

## Patient and Surgeon Experience

The mean pain perception on the VAS was 1.8 (range 0-6),



**Figure 2. Concentric procedure strategy for PRP, which allows for treatment of each area with the same power.**

which was correlated with the surgeon's evaluation for each session (mean score = 9; range 2-10). Pain response during laser treatment varied among patients and depended on the treated area.

Glare perception also showed variability, with an average score of 2.8 (range 0-9) and was not correlated with lens status or cataract grade. Glare perception seemed to be highly subjective and not predictable.

### Benefits of the 577-nm Multispot Laser

Because this was not a direct comparative study, we compared our results obtained with the Supra Scan 577 with those reported in the literature with traditional single-spot or semi-automated 532-nm lasers.

The fluence in our study was an average of 435 mW and 5-7 J/cm<sup>2</sup> vs averages of 630 mW and 47 J/cm<sup>2</sup> in a study using traditional single-spot 532-nm lasers.<sup>4</sup> This was consistent with a previous study that achieved the treatment endpoint with 26% lower power using the 577-nm laser vs the 532-nm laser.<sup>2</sup> The reduced fluence decreased collateral damage to surrounding tissue compared with traditional single-spot lasers.

In our study, the CRT was stable even in single-session PRP, confirming Muraly et al's conclusion that single-session PRP is safe and effective.<sup>5</sup>

The 577-nm yellow laser was very interesting in cases of ocular opacities. We were able to create fewer glares, and the laser went through the cataract with lower power. This wavelength could be the answer to the limitations of the 532-nm multispot laser: scattering and ocular opacities. Nevertheless, it is very useful to have power up to 2,000 mW for complex cases with strong cataracts and for which surgery is not an option.

Another advantage of the 577-nm laser is short duration, which may be associated with less pain because of decreased thermal diffusion into the choroid, which is rich in sensory nerves. In addition, total PRP time is reduced due to fewer laser sessions (1-3 vs 4-6). As a result, the use of a 10- to 20-ms pulse duration appears to correspond to the optimal compromise between favorable impact of speed (total time) and reduced collateral damage (inflammation, pain).

### STUDY 2

This was a case series of 50 patients presenting either with severe nonproliferative diabetic retinopathy (20 cases) or established PDR (25 cases in the early stages and five pre-papillary cases) who underwent laser PRP at Clinique Les Eaux Claires, Baie-Mahault, Guadeloupe, between June and November 2012.

We used two different lasers in this study: a GYC-

1000 (Nidek Co., Ltd., Gamagori, Aichi, Japan) single-spot 532-nm laser and a Supra Scan 577 (Quantel Medical, Cournon d'Auvergne, France) multispot 577-nm laser. We performed complete (PRP) treatment, using both lasers on each patient, but we alternated between the lasers during each session.

The treatment zone was divided horizontally into an upper and a lower zone: we treated one with the single-spot 532-nm technique and the other with the multispot 577-nm technique. A total of 300-500 burns were delivered per session, with wide-angle contact lenses.

At each laser session, all patients were asked three questions, in a purely comparative manner (ie, not in terms of a scale):

- Was the pain after the laser session more or less intense than last time?
- Was the pain during the laser session more or less intense than last time?
- Was the duration of the laser session shorter or longer than last time?

Several studies have already been published that have used cross-sectional OCT images to monitor laser scarring between the RPE and the inner retinal layers. As a result, we focused on the more macroscopic aspect of the scarring. We obtained simple color (C) fundus, and autofluorescence (AF) images, using a Canon (Tokyo, Japan) CR2-Plus Retinal Camera.

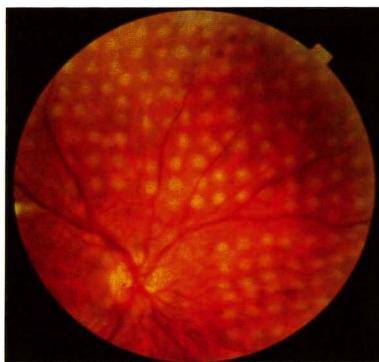
The parameters (mean values) used with the GYC-1000 laser were 200 mW/150 ms/360  $\mu$ m per interval of 200 ms. For the Supra Scan 577, the parameters were 400 mW/10 ms/360  $\mu$ m, with no repetition mode and a nine-point square pattern.

Temporary treatment discontinuation before the end of the PRP treatment, due to severe crystalline lens opacity, occurred in seven cases, four of which were bilateral (ie, a total of 11 eyes). In five cases, this was solely attributable to the use of the green laser, either due to the impossibility of marking or the intolerable pain level caused by the intensity required for the procedure. In the two other cases, even the yellow laser was equally incapable of providing a satisfactory solution. In all cases, the decision was made to operate nonetheless, because it was still anatomically significant and functionally unfavorable.

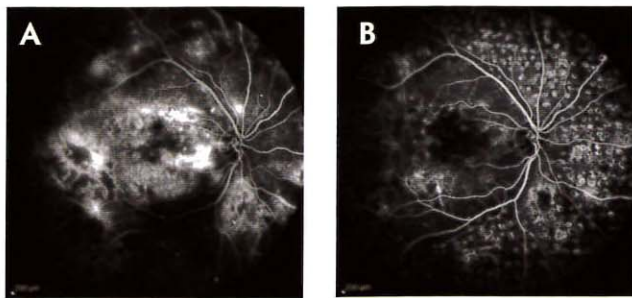
Ultimately, all patients were able to undergo a complete, effective PRP treatment that halted the progression of the PDR.

### Patient Experience

Patient experience results are expressed as the averages of the sessions with the green laser and for the sessions with the yellow laser.



**Figure 3. PRP with 4 x 4 arrays in proliferative diabetic retinopathy. We used Spectralis SD-OCT (Heidelberg Engineering, Heidelberg, Germany) to assess central retinal thickness.**



**Figure 4. Proliferative diabetic retinopathy regression at the last follow-up visit: first visit angiogram (A) and last visit angiogram (B) with regression of the neovascularization.**

The residual pain after the laser session was mainly due to the patients' reference memory from previous laser sessions, which reflected the potential anxiety regarding the next session. Approximately 30% of the patients in each group experienced similar pain intensity, regardless of the laser used (Figure 5); this finding highlighted that laser treatment remains a painful intervention for patients and should be considered as such by the physician. Nevertheless, more than twice as many patients felt that they had experienced less pain with the 577-nm laser.

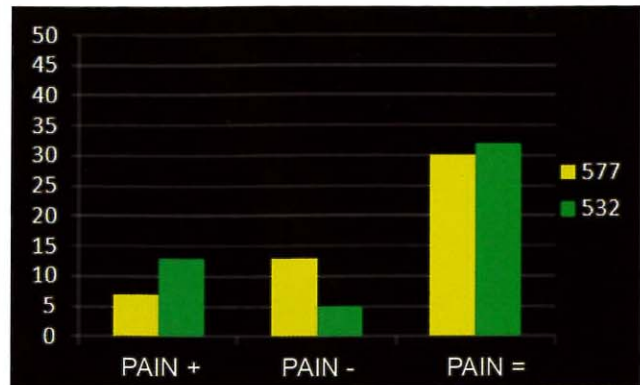
With regard to pain during the laser session, the study strongly favored the 577-nm wavelength (Figure 6). This, despite that approximately 15% of patients considered that they experienced more pain during the sessions with the 577-nm multispot laser than during the sessions with the 532-nm single-spot laser; this corresponds more to the cumulative effect of the sessions, especially in sensitive patients. Opting for a comparative mode, which alternated at each session, made it possible to pinpoint this trend over the week. However, the difference was not so pronounced that the patients refused to continue with the treatment.

Finally, for the patients' perception of the length of the laser session (Figure 7), the debate only concerned the single-spot or multispot aspect, with no conclusion regarding the wavelength. It was less unanimous than expected, with one-third of patients reporting that a laser session was always too long.

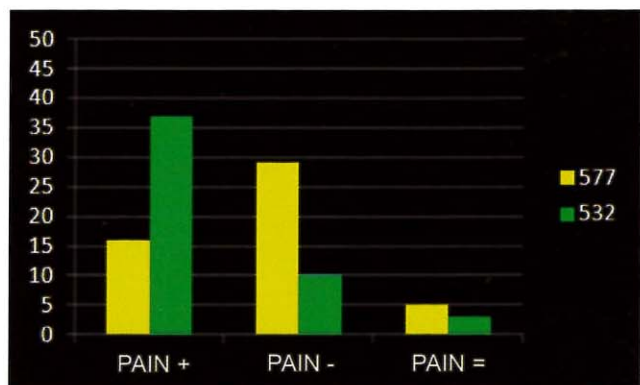
### Monitoring via C/AF Retinal Imaging

The example of scarring at six months (ie, relatively early in terms of PRP monitoring) presented here showed that differences in the size and depth of the scars were already apparent at this time (Figure 8). This corroborated OCT conclusions, suggesting that treatment using a multispot 577-nm laser is much less destructive.

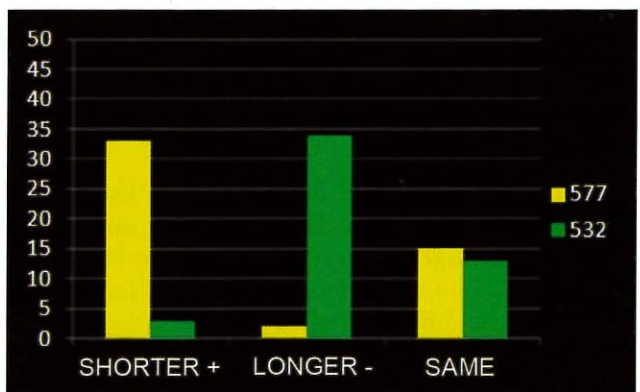
The main limiting factor was the relative crystalline opacity, restricting the number of usable images at the time. However, these can be reintegrated over the longer term, following cataract surgery. The images after two years should be much more significant, and they will then be paired with automated perimetry.



**Figure 5. Percentages of patients experiencing more, less, or similar pain after the 577-nm and 532-nm laser sessions.**



**Figure 6. Percentages of patients experiencing more, less, or similar pain during the 577-nm and 532-nm laser sessions.**

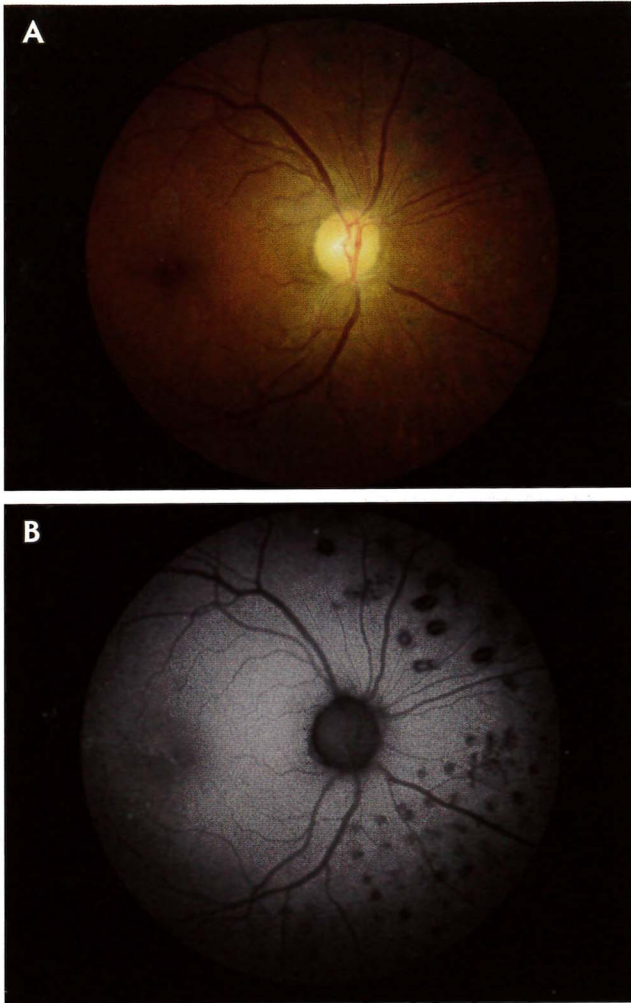


**Figure 7. Percentages of patients considering the length of the laser session to be longer, shorter, or of similar duration to preceding sessions.**

### SUMMARY

Our clinical experience with the multispot yellow 577-nm laser demonstrated several advantages of this treatment approach, suggesting an important advancement in PRP treatment.

Compared with traditional single-spot photocoagulation, the multispot 577-nm laser reduced the overall



**Figure 8.** Example of scarring at six months, nasal retina of the right eye: inferior part treated with the 577-nm laser (A) and superior part treated with the 532-nm laser (B).

treatment time by one-third. Because a higher laser power compensates for short pulse duration without side effects. We can now manage shorter settings with more burns, less pain for the patient, and improved ease-of-use for the surgeon. With less difficulty and less collateral damage, we can achieve similar efficacy to single-spot procedures with the 532-nm single-spot laser. **RP**

## REFERENCES

1. Lock JH, Fong KC. An update on retinal laser therapy. *Clin Exp Optom.* 2011;94:43-51.
2. Sanghvi C, McLauchlan R, Delgado C, et al. Initial experience with the Pascal photocoagulator: a pilot study of 75 procedures. *Br J Ophthalmol.* 2008;92:1061-1064.
3. Nagpal M, Marlecha S, Nagpal K. Comparison of laser photocoagulation for diabetic retinopathy using 532-nm standard laser versus multispot pattern scan laser. *Retina.* 2010;30:452-458
4. Blumenkranz MS, Yellachich D, Andersen DE, et al. Semiautomated patterned scanning laser for retinal photocoagulation. *Retina.* 2006;26:370-376.
5. Muraly P, Limbad P, Srinivasan K, et al. Single session of Pascal versus multiple sessions of conventional laser for panretinal photocoagulation in proliferative diabetic retinopathy: a comparative study. *Retina.* 2011;31:1359-1365.